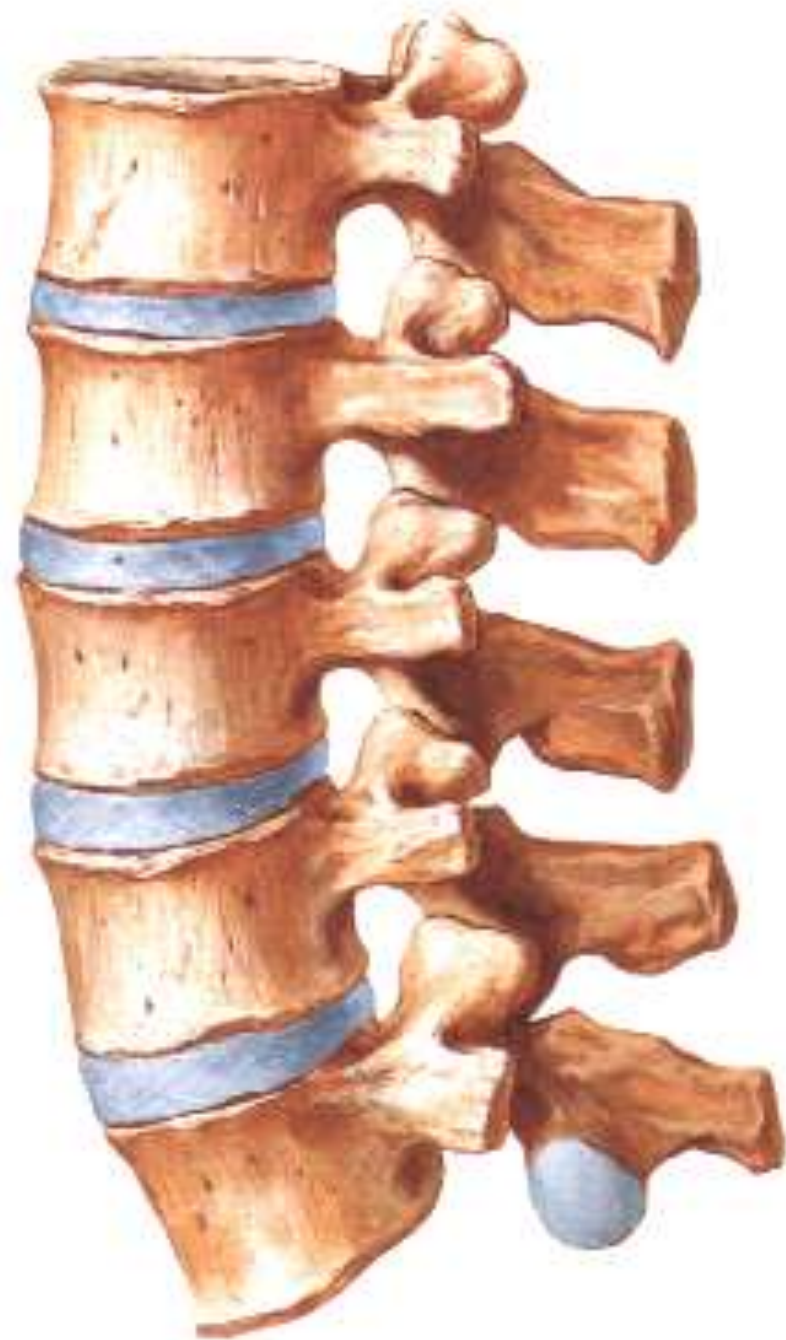
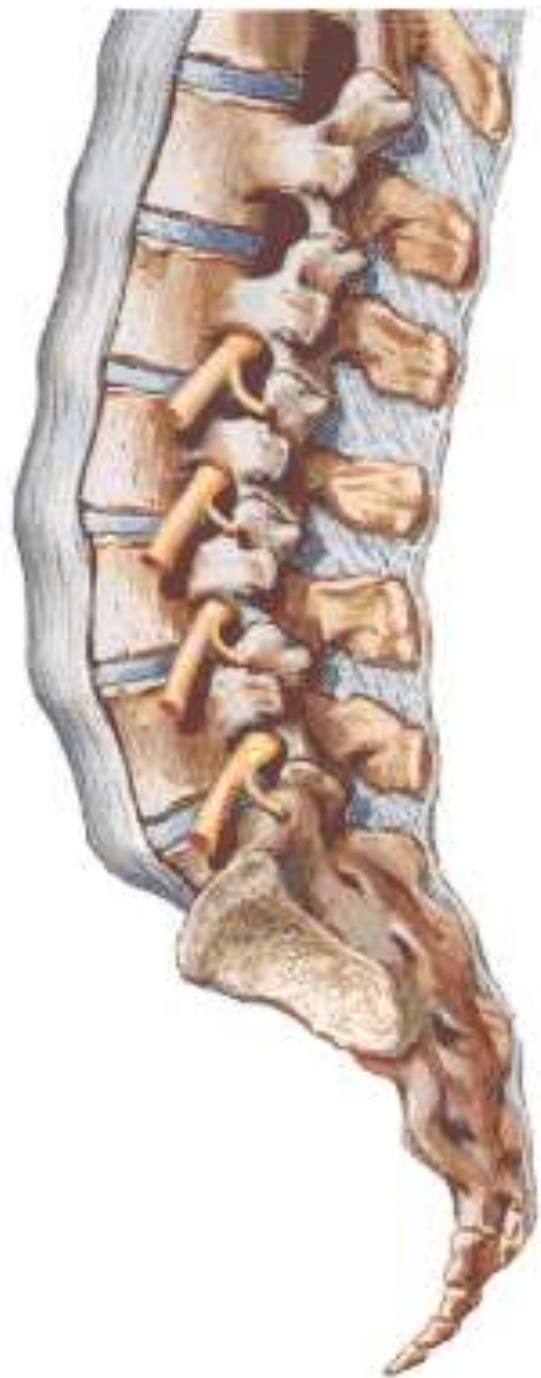
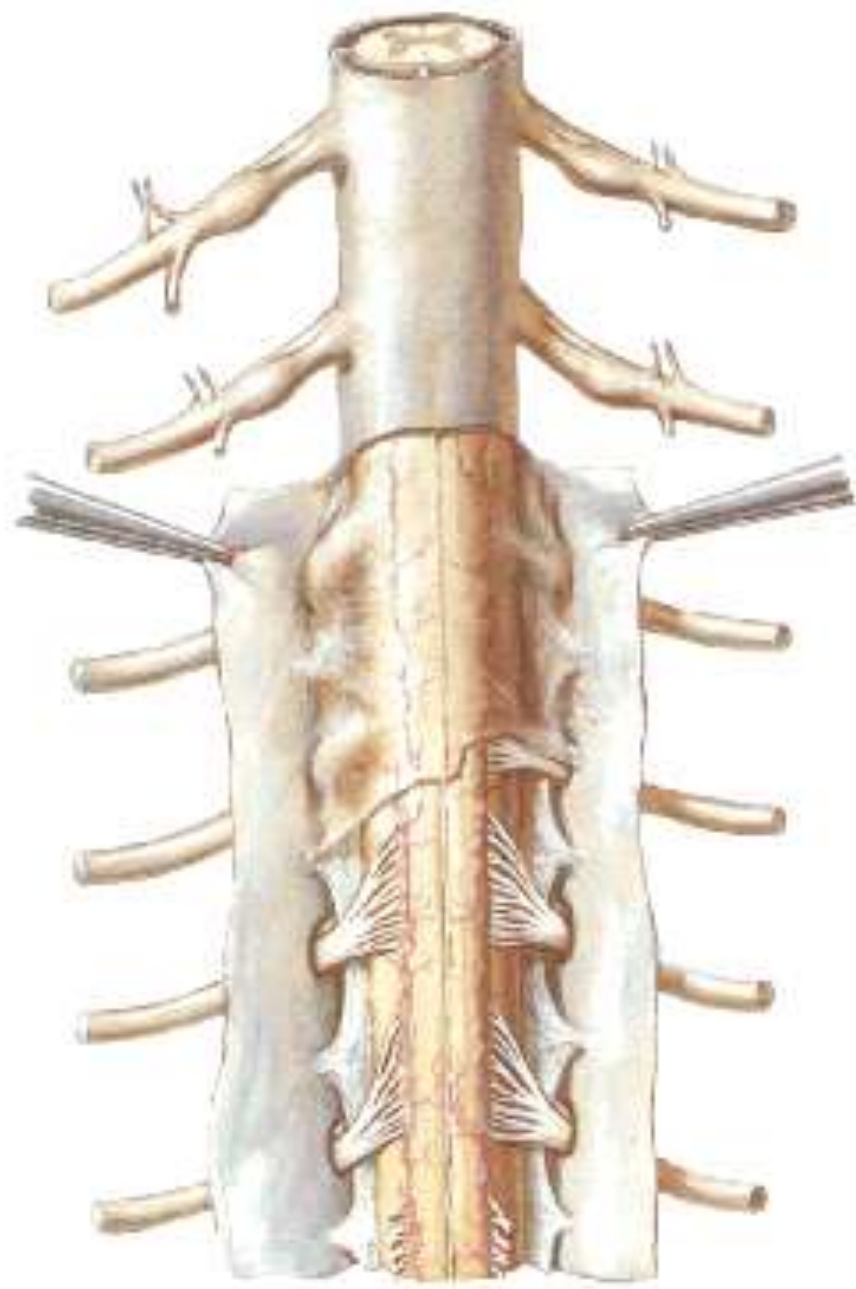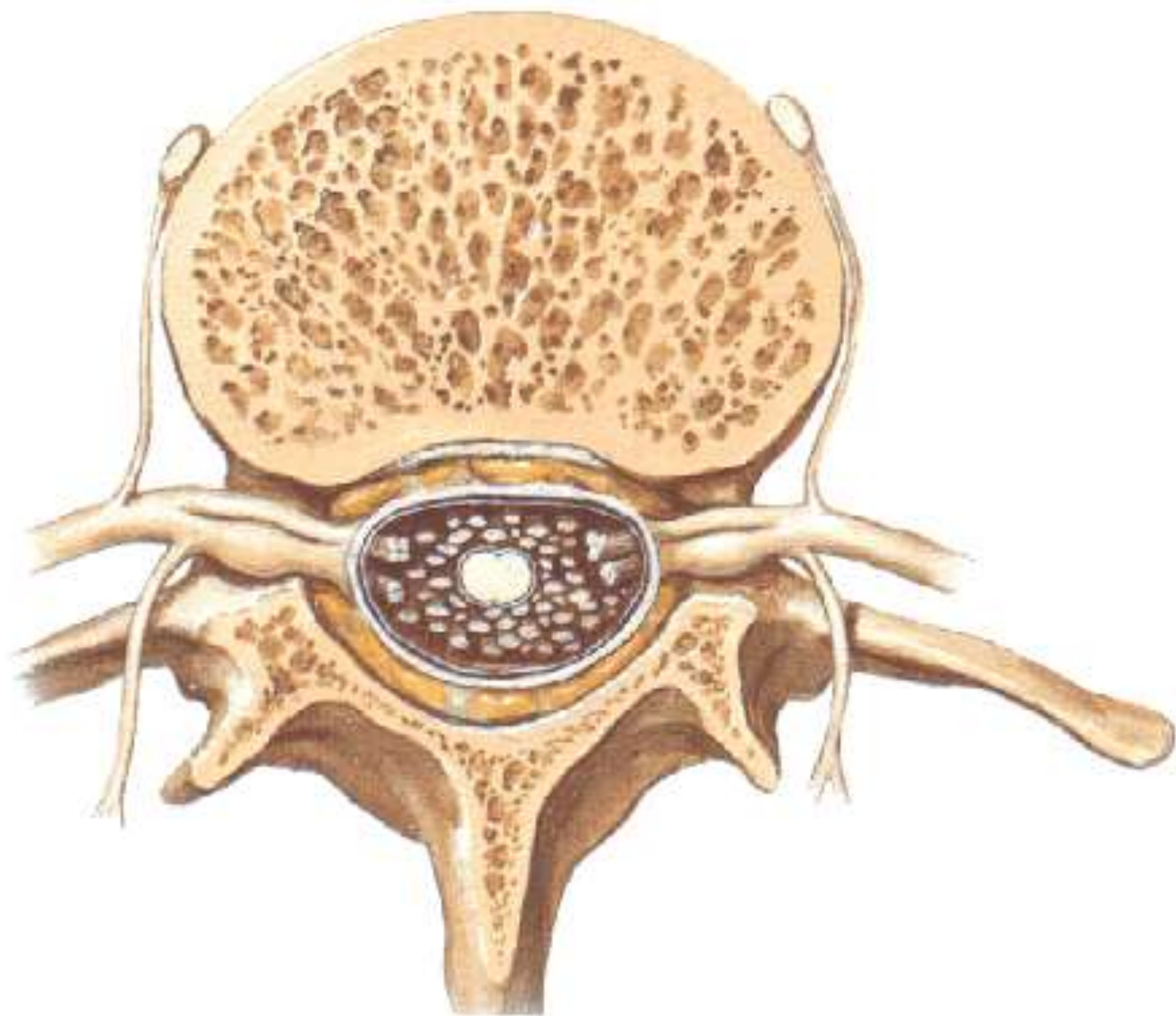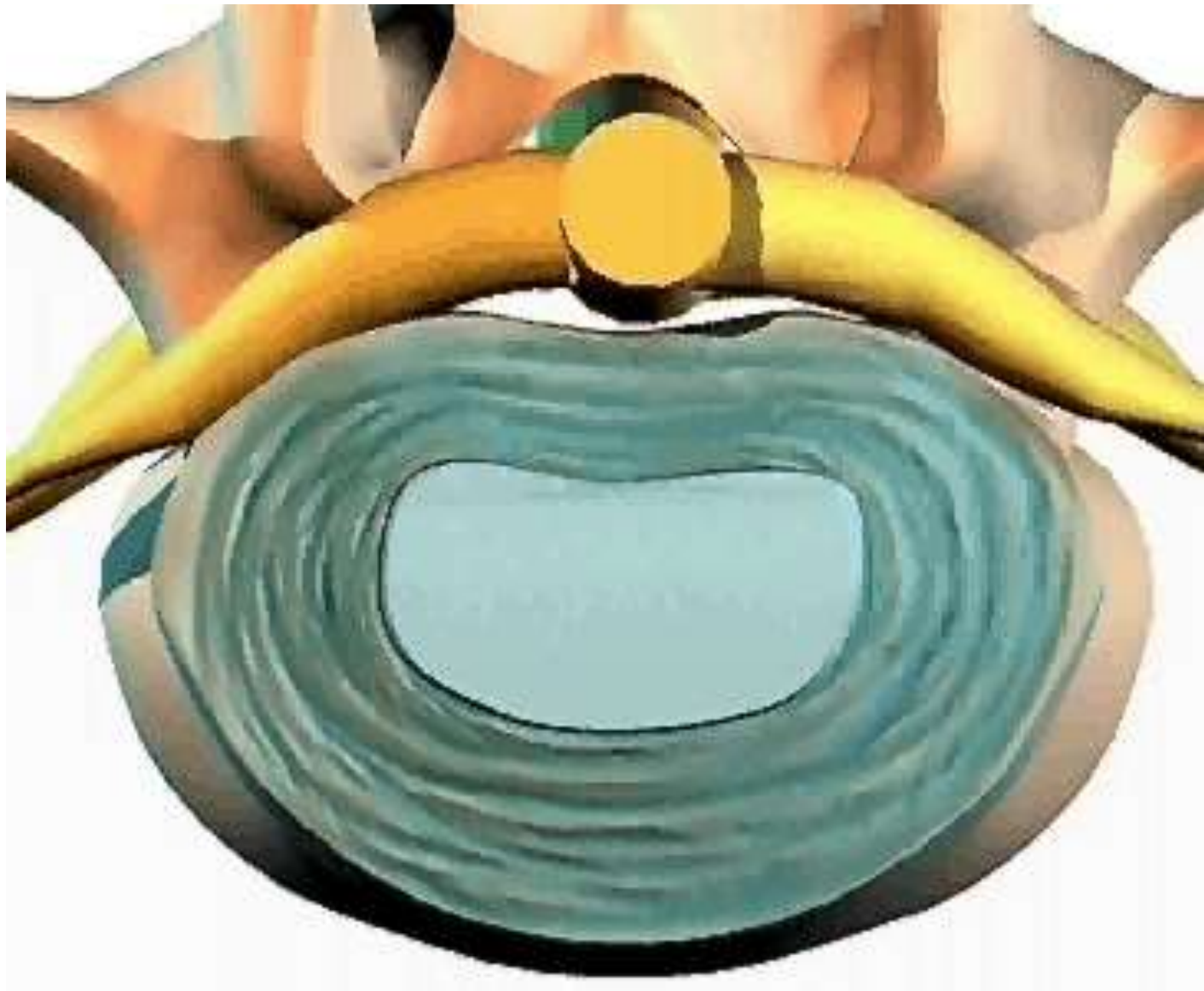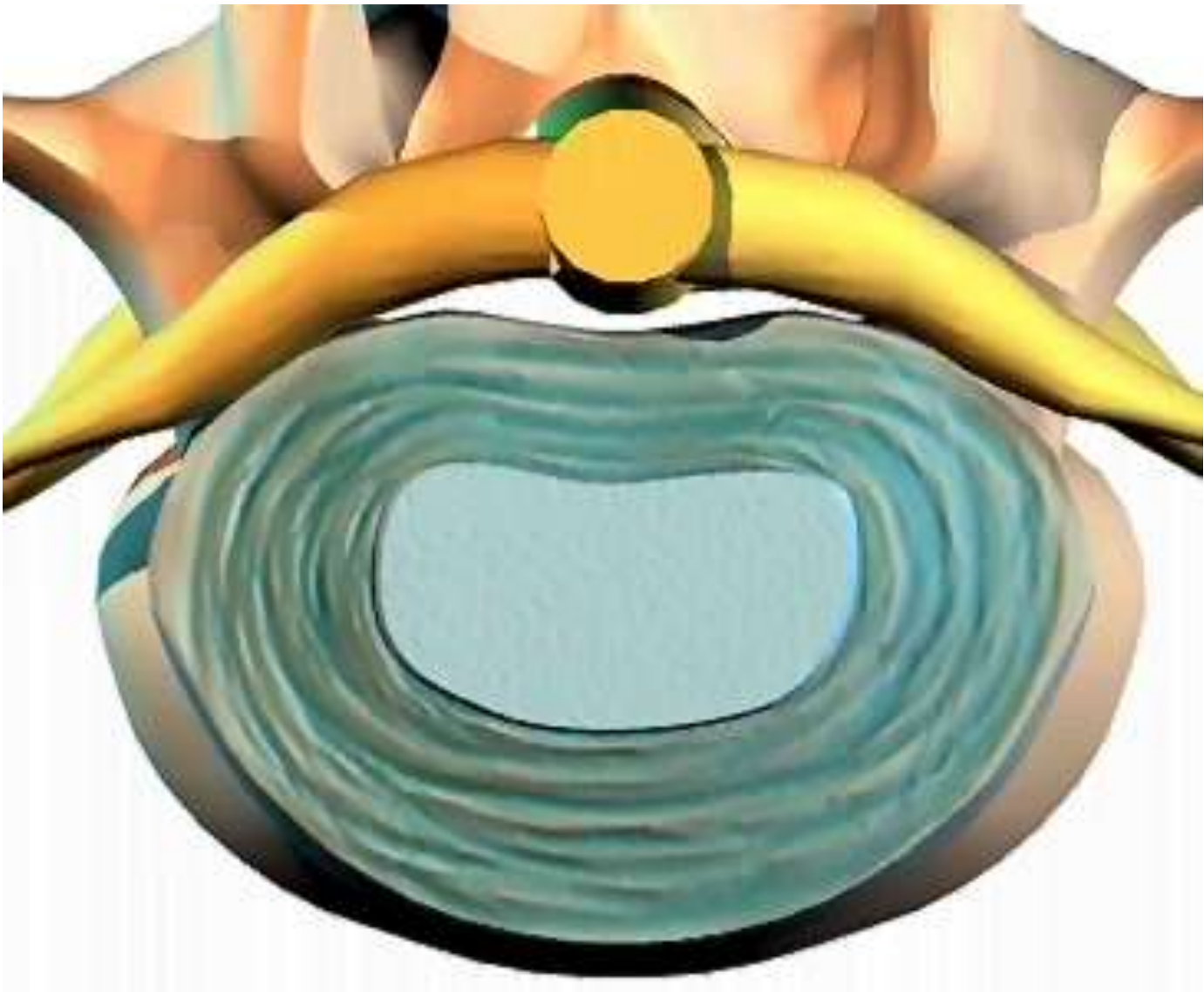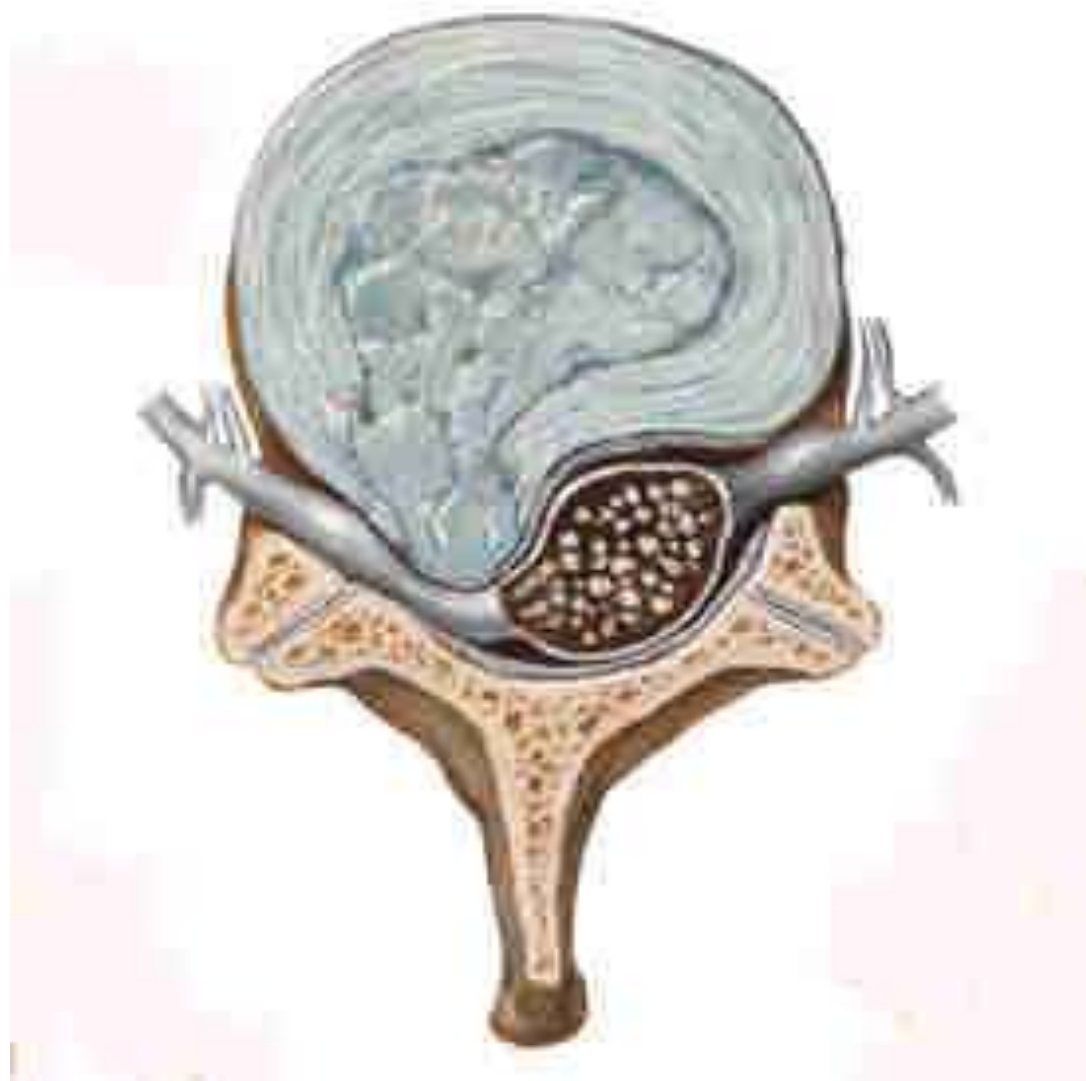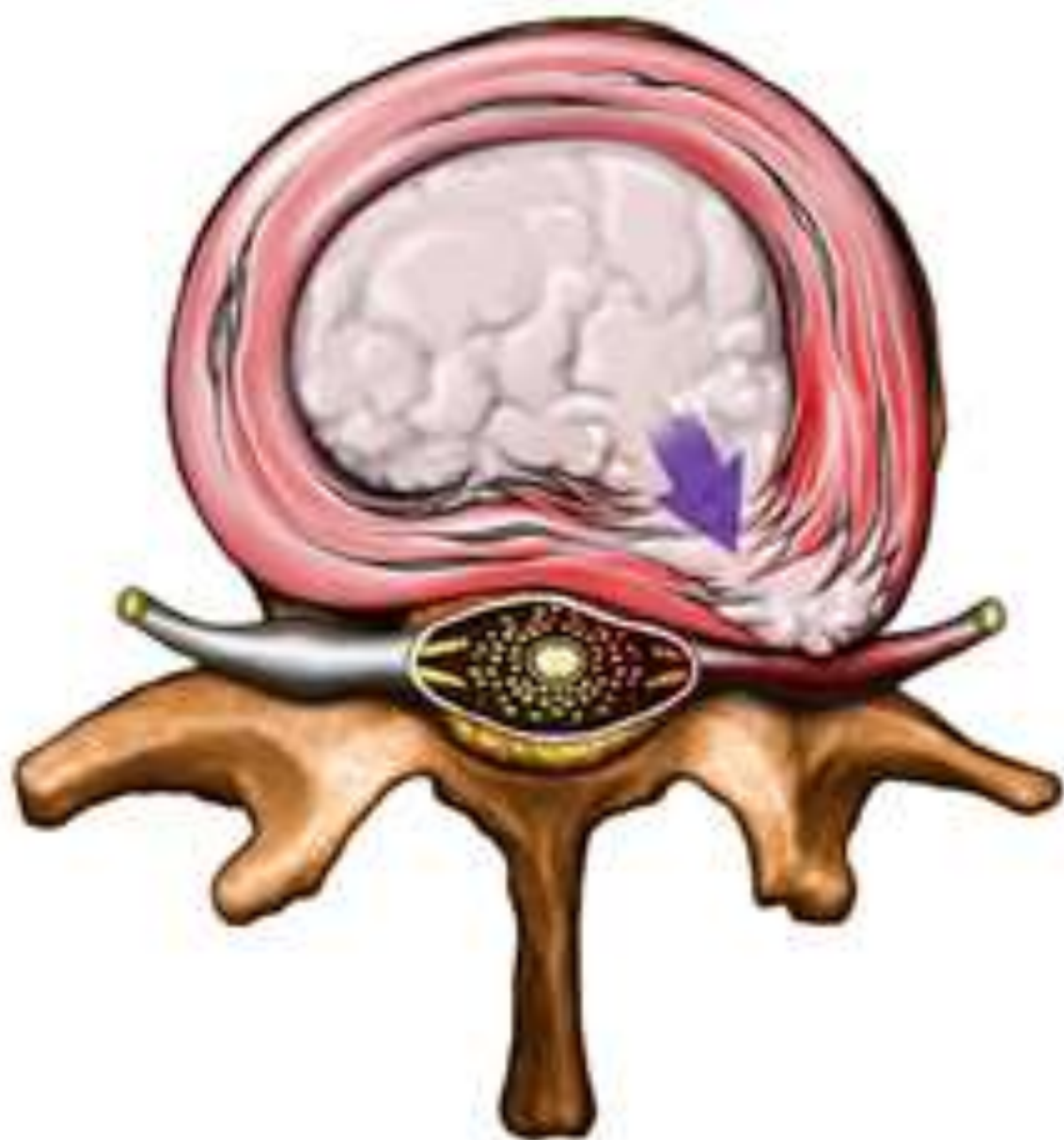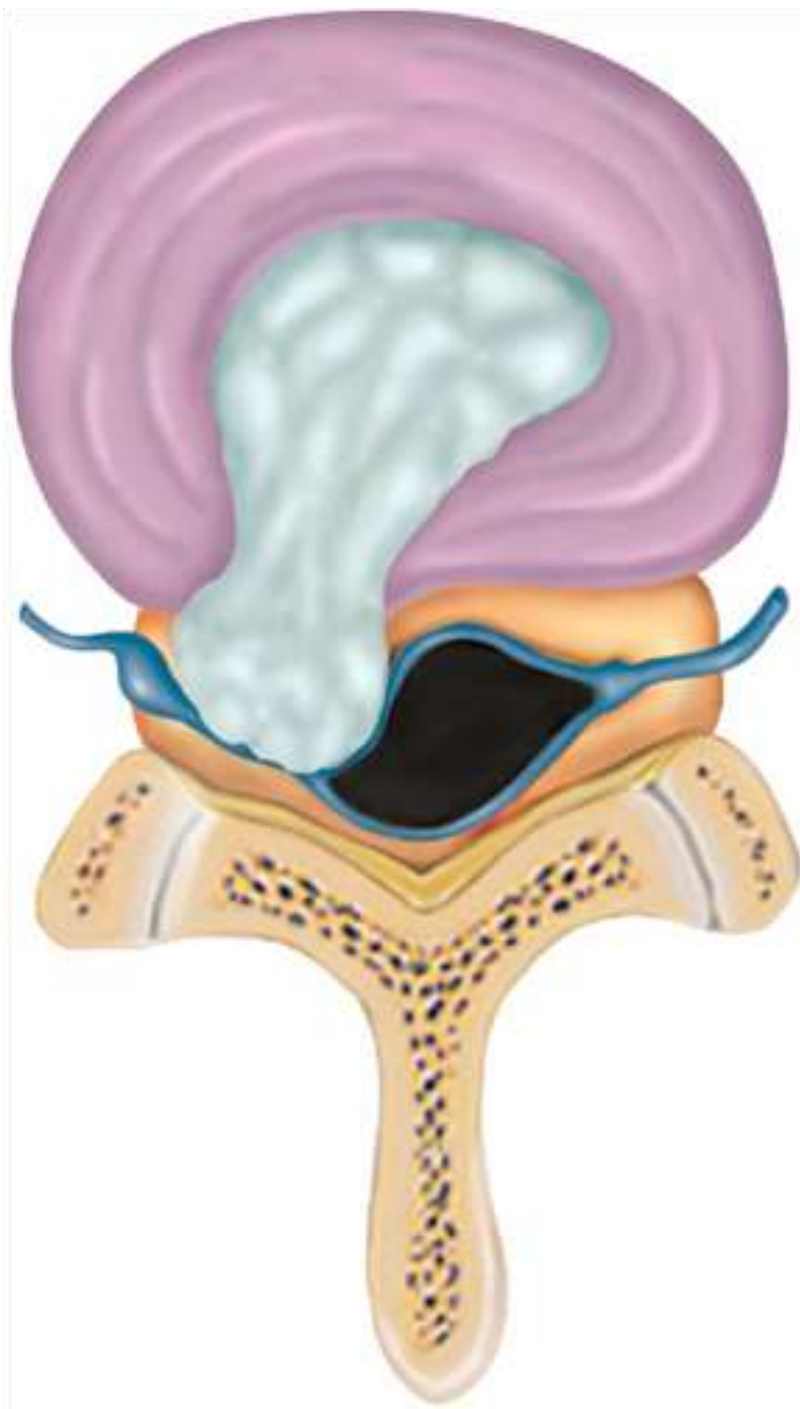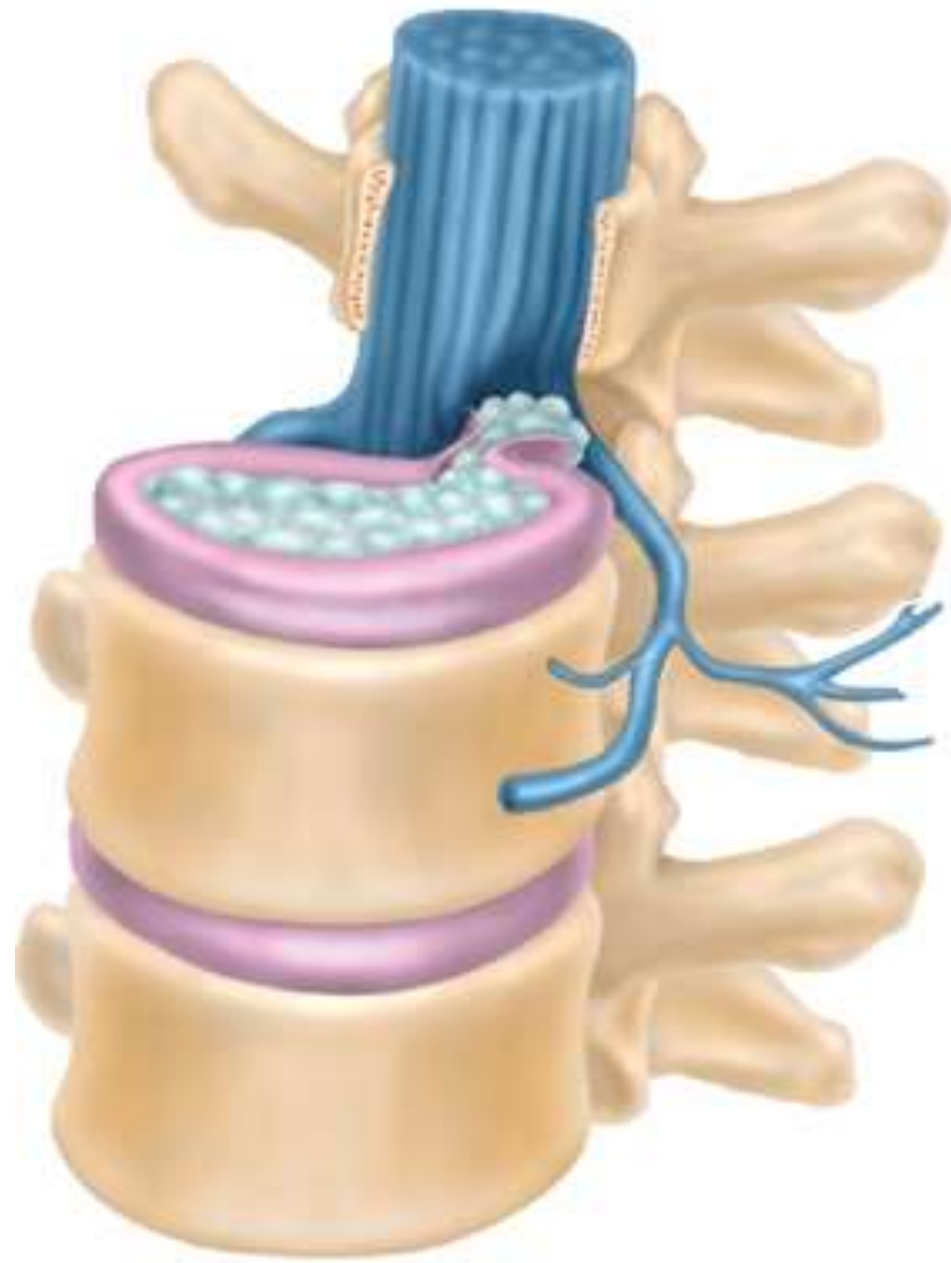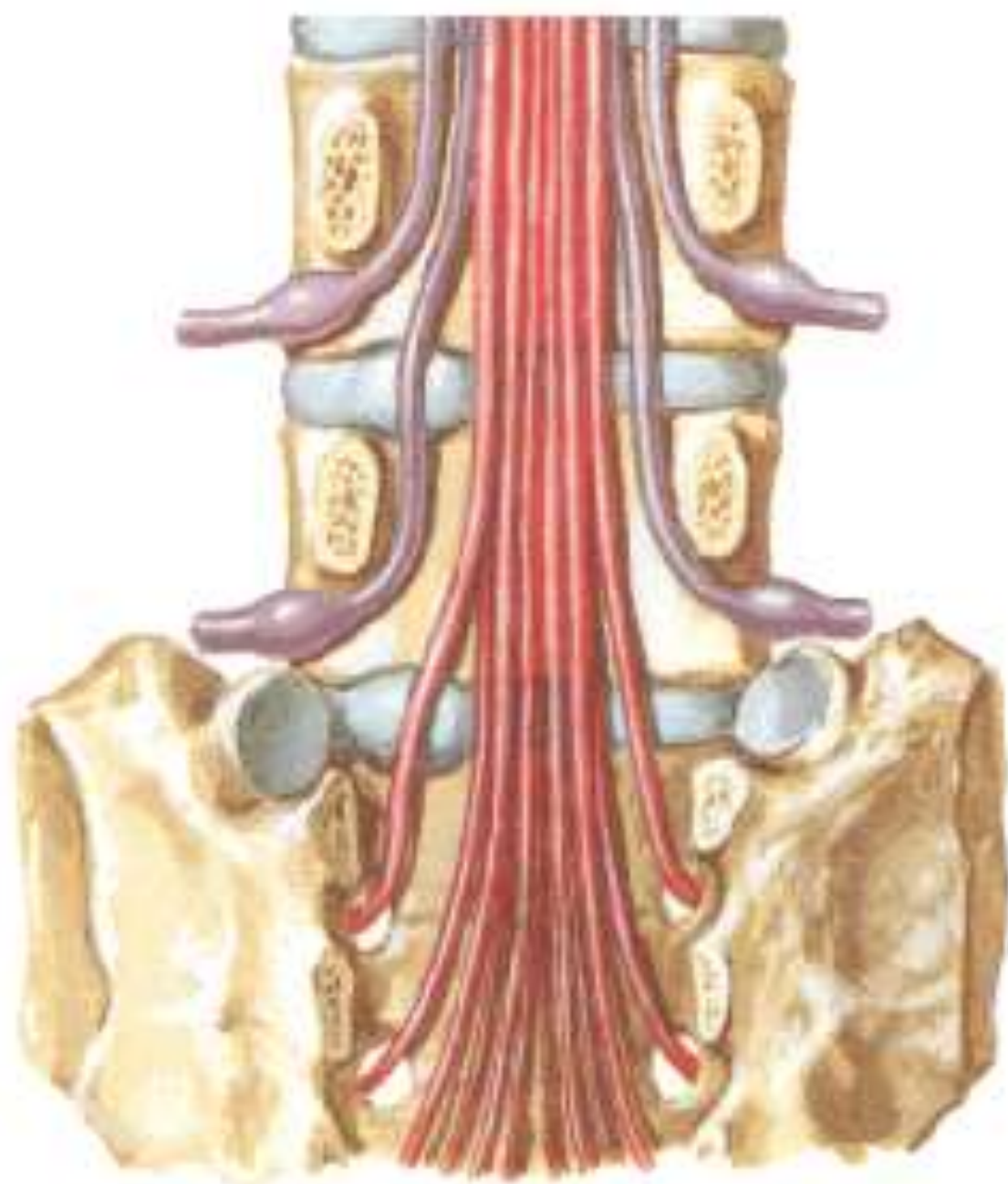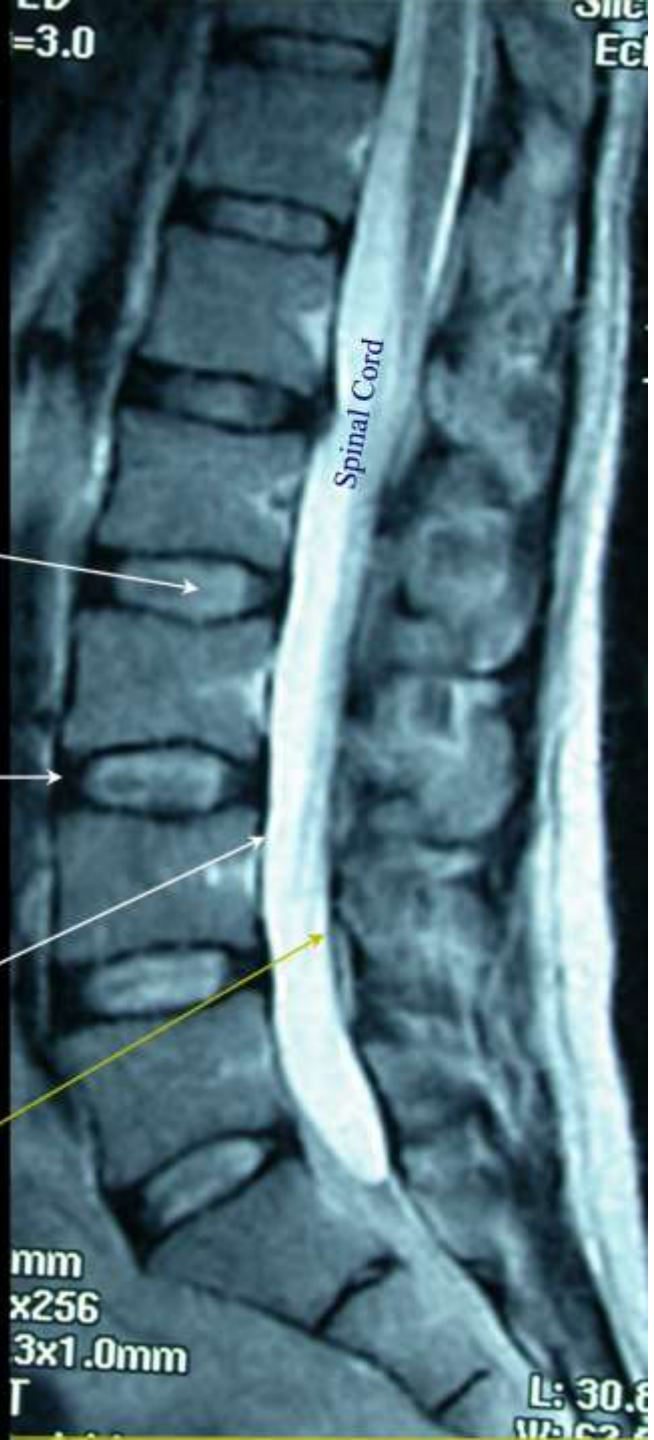
Normal MRI
This is an example of a normal MRI (except for the small disc buldge at L1-2. Note the appearance of the normal disc. A normal disc is well hydrated and has a whitish appearance on the MRI. The outer portion of the disc is the tough annulus which appears black. The spinal canal is wide and cylindrical.

Nucleus of Discs with normal whitish appearance

Annulus of disc with normal solid black appearance. There are no cracks or herniations posteriorly.

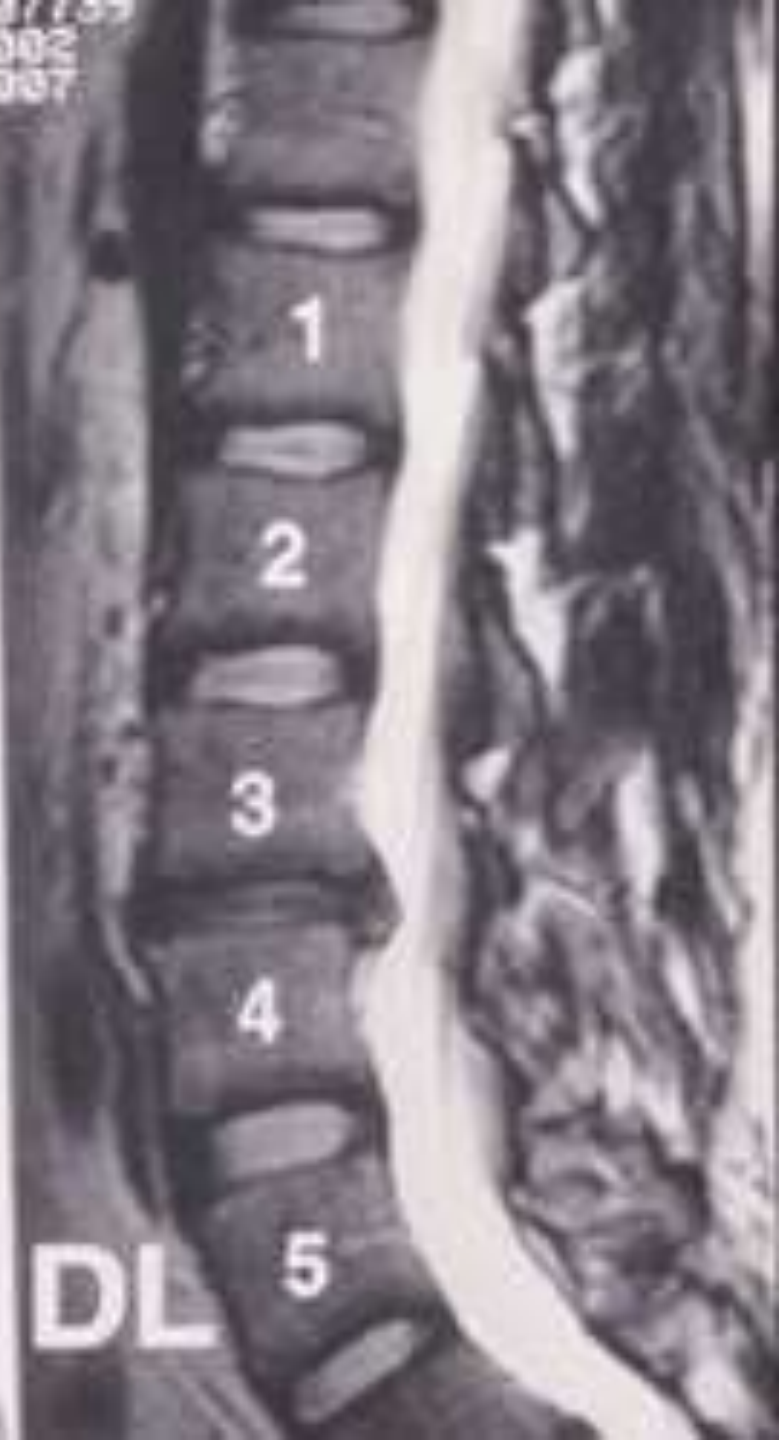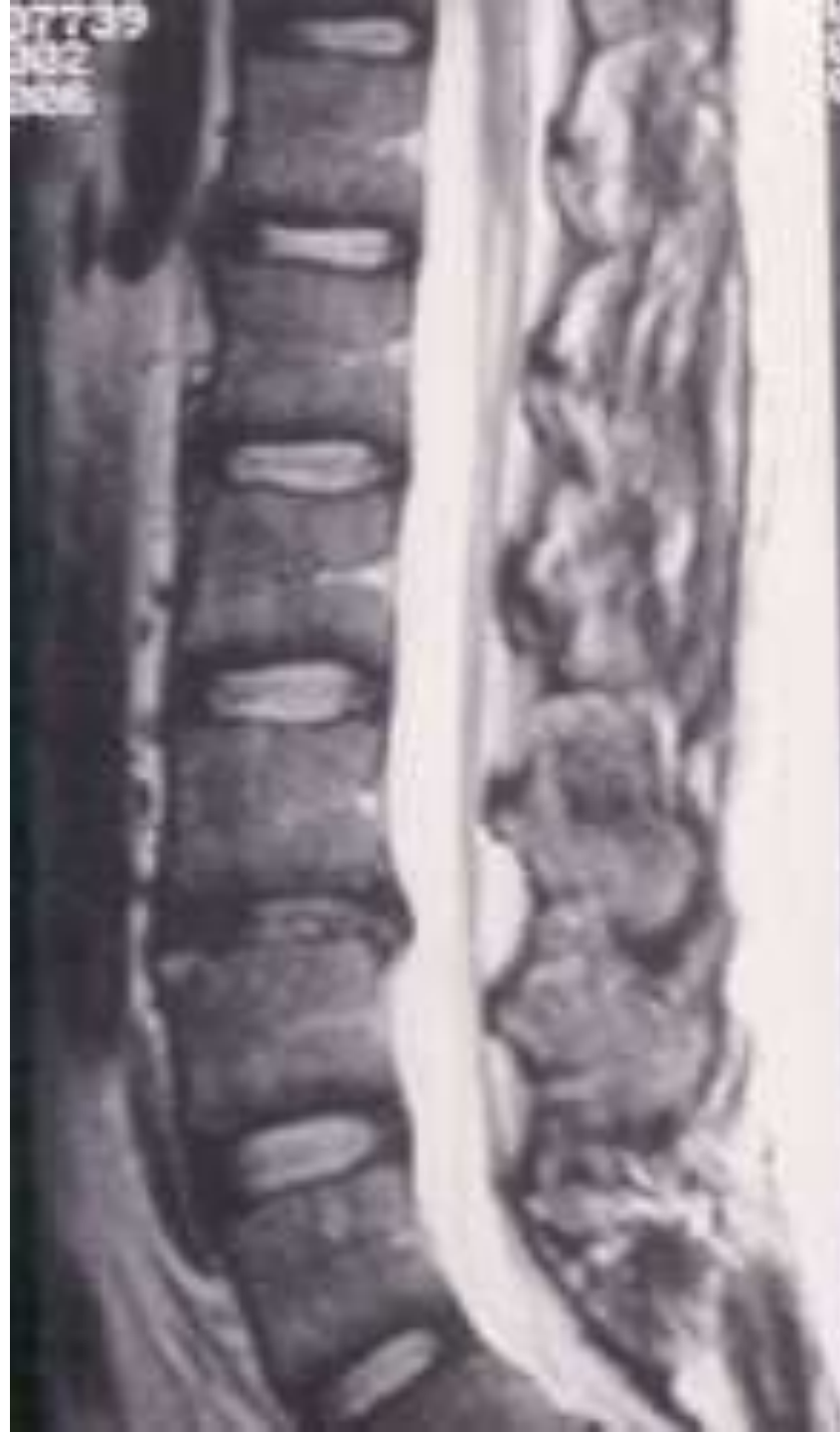Smooth cylindrical shape of spinal cord without any disc buldges on the cord.

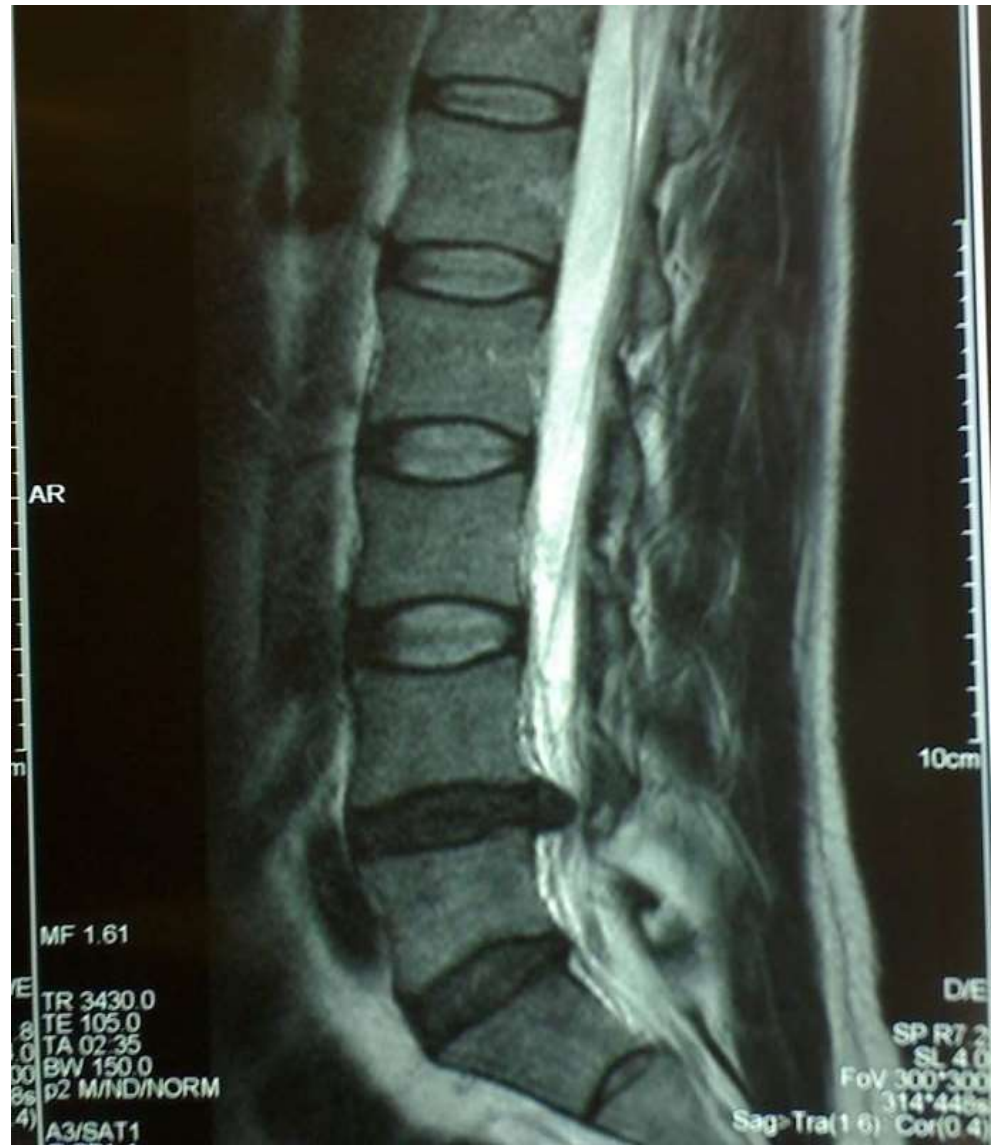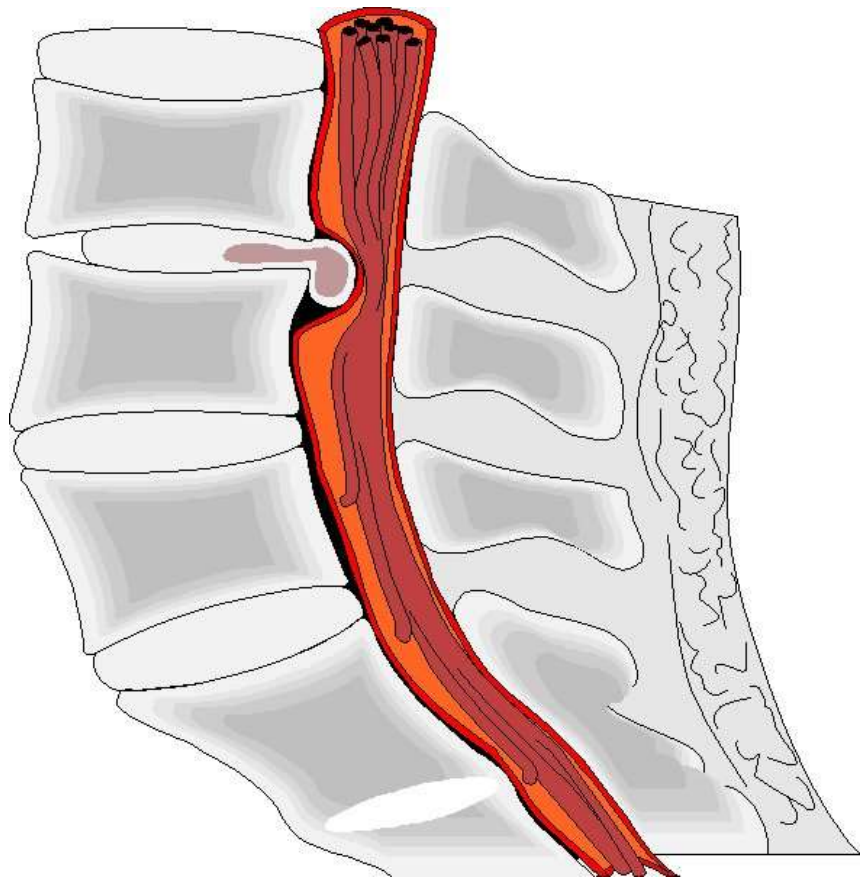
No Posterior Bone Spurs are present that would cause cord compression

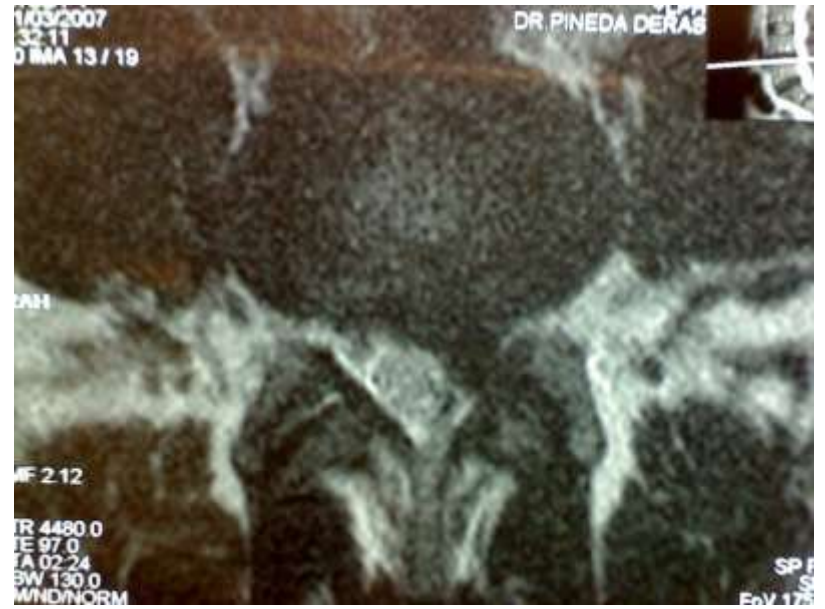
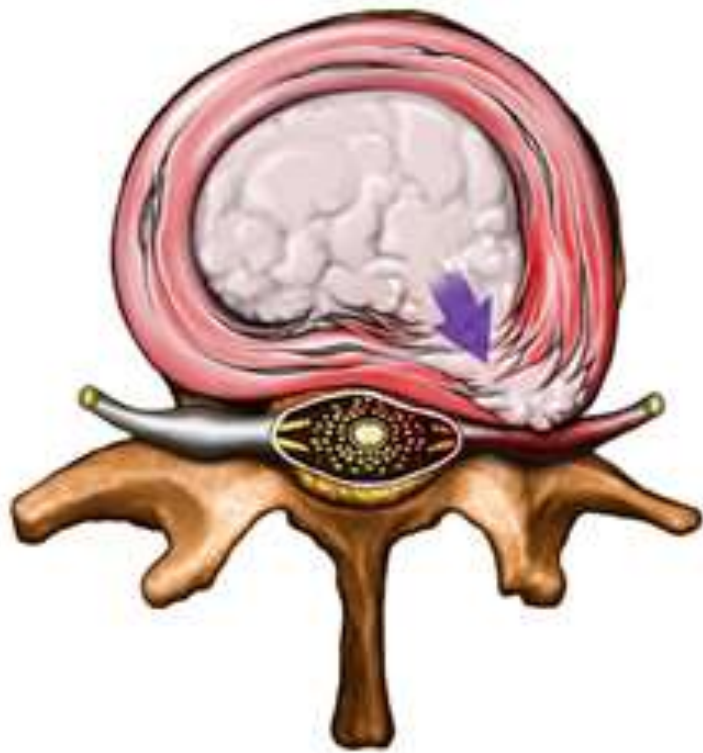

07739
002
006

17739
002
007







010C0

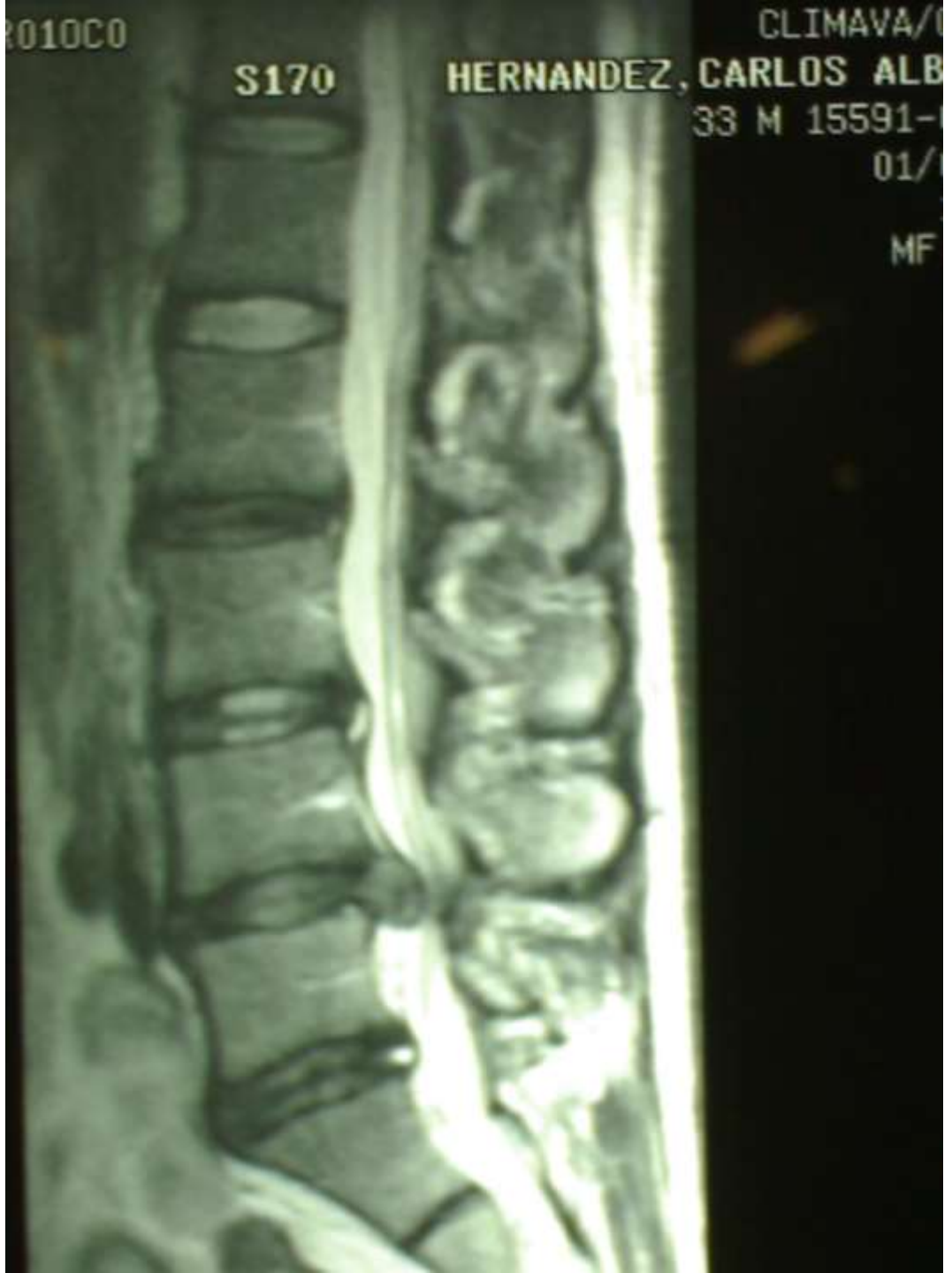S170

HERNANDEZ, CARLOS ALB

33 M 15591-

01/

MF



Ex:15591
Se:3/5
Im:16/18
OAZ: 38.9

A1

HERNANDEZ, CARLOS ALBERTO

S3 M 15591-07 OL
01/03/07
16:02
MF: 1.5

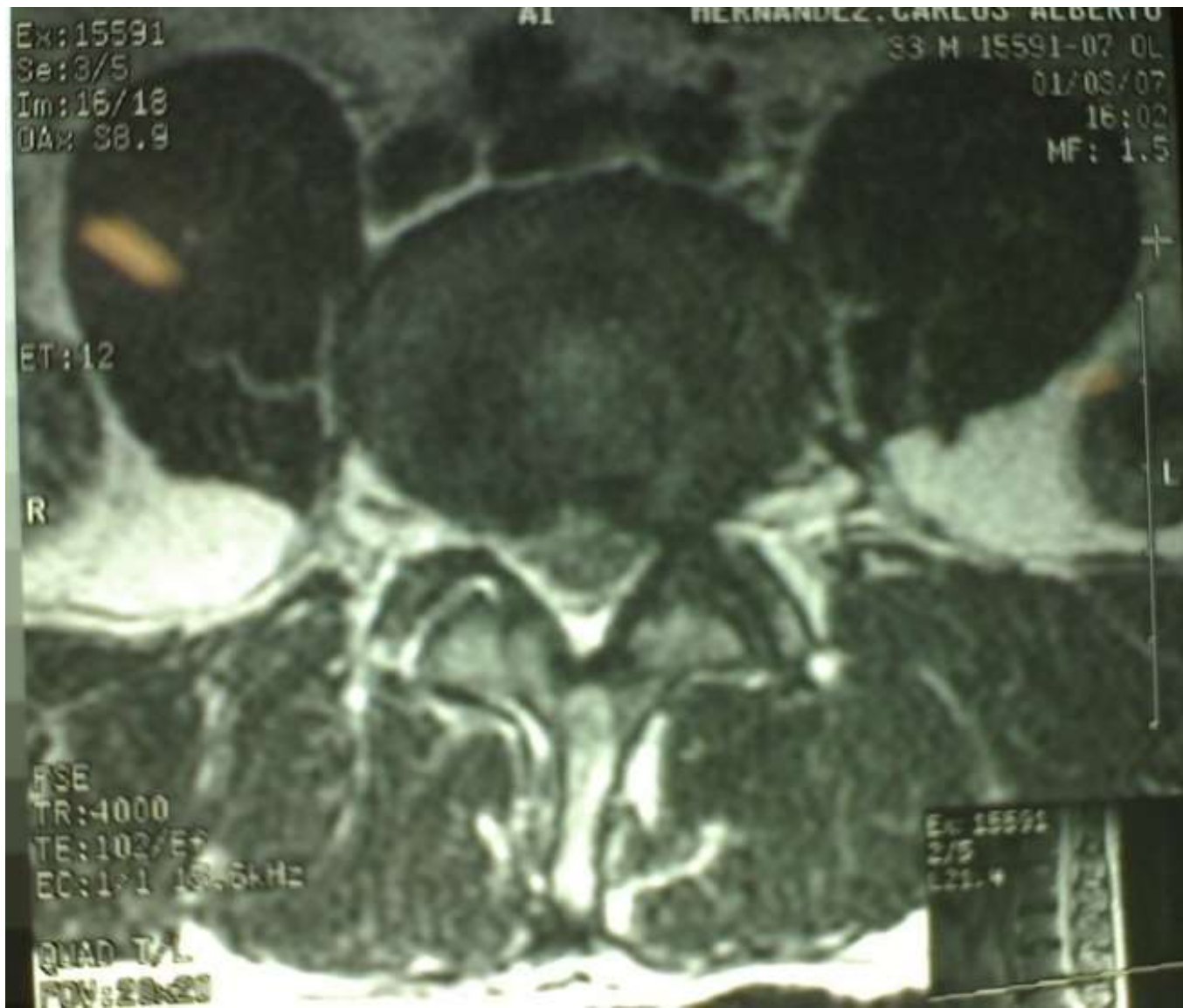ET:12

R

FSE
TR:4000
TE:102/59
EC:1-1 16.6kHz

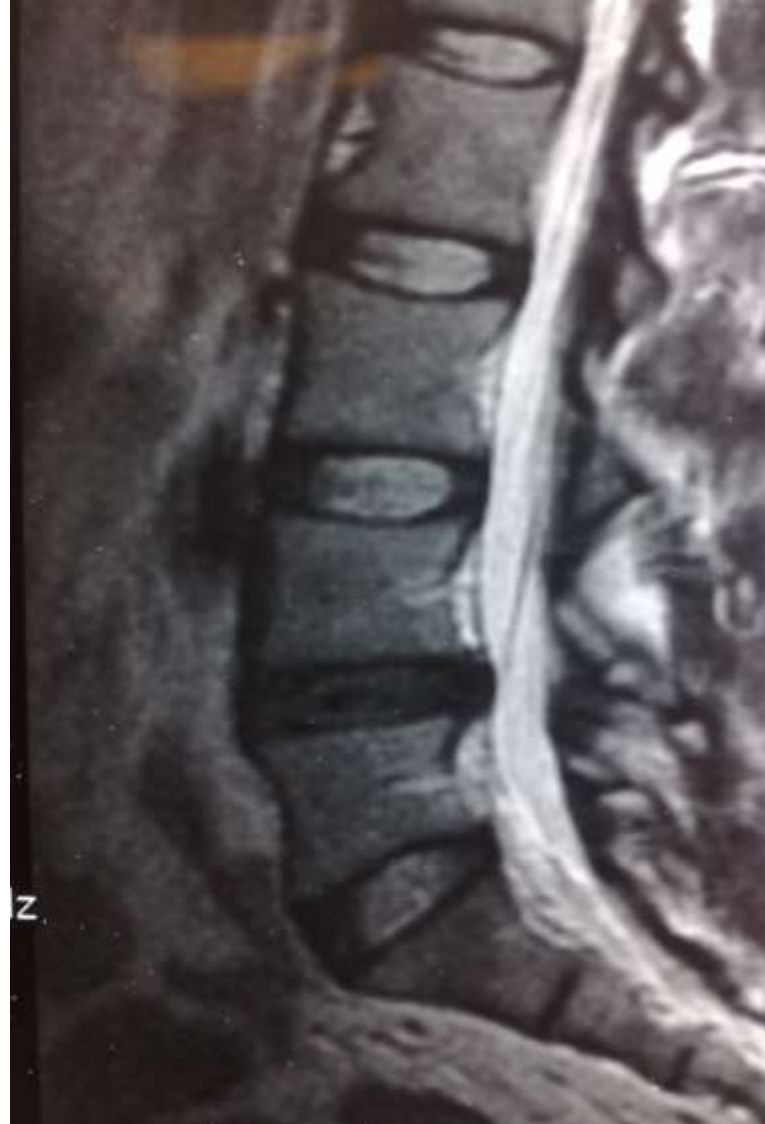QIAD T1
FOV: 23x23

Ex: 15591
2/5
L21. +



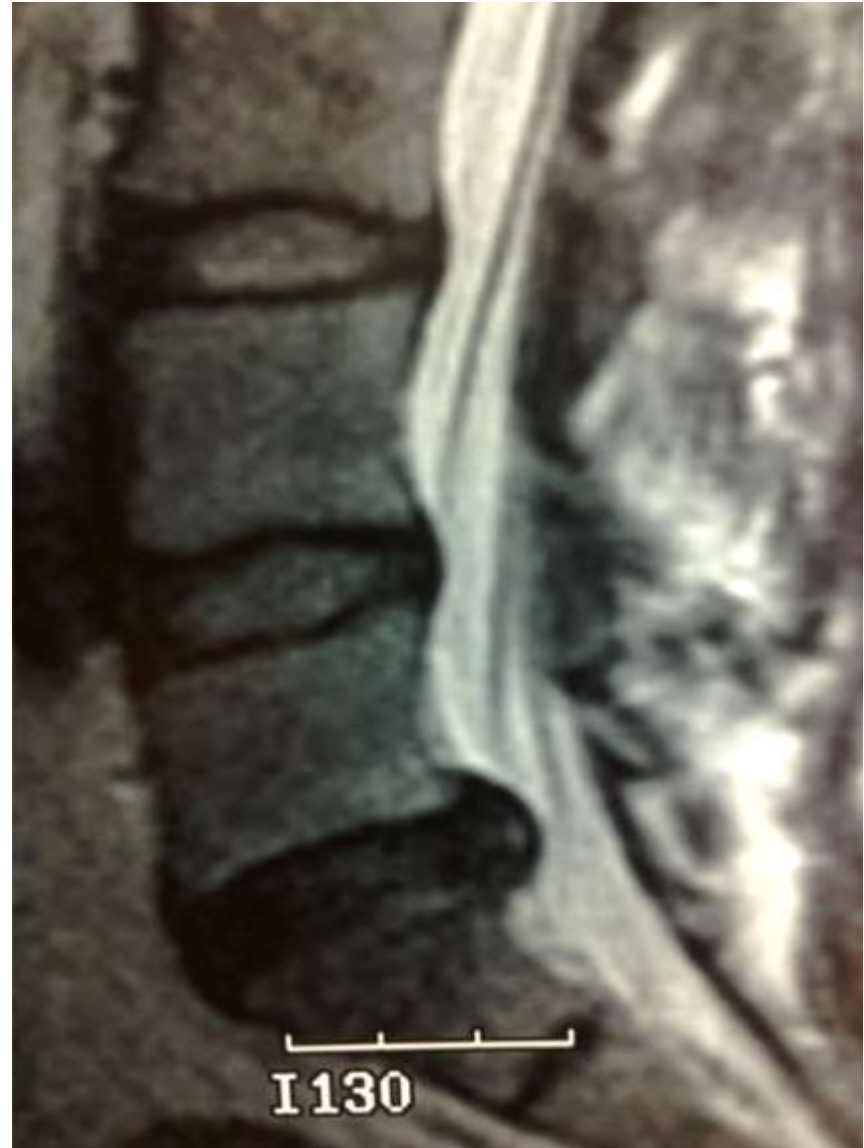2381-08

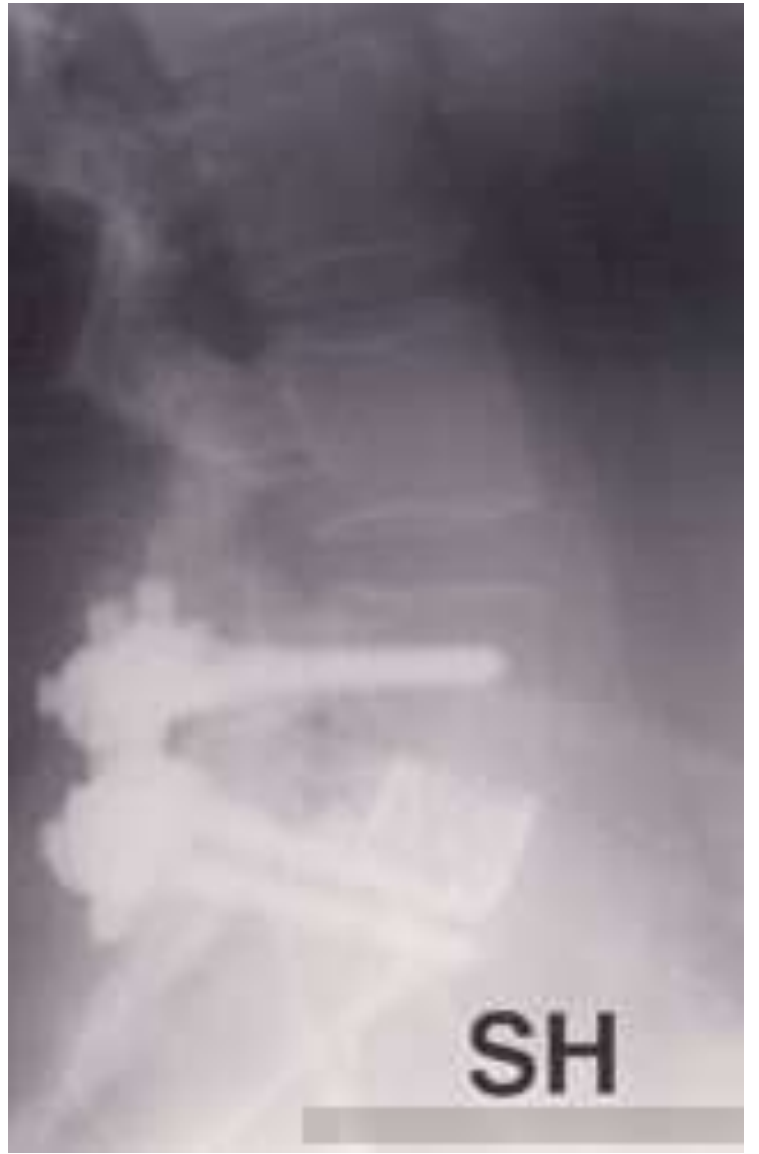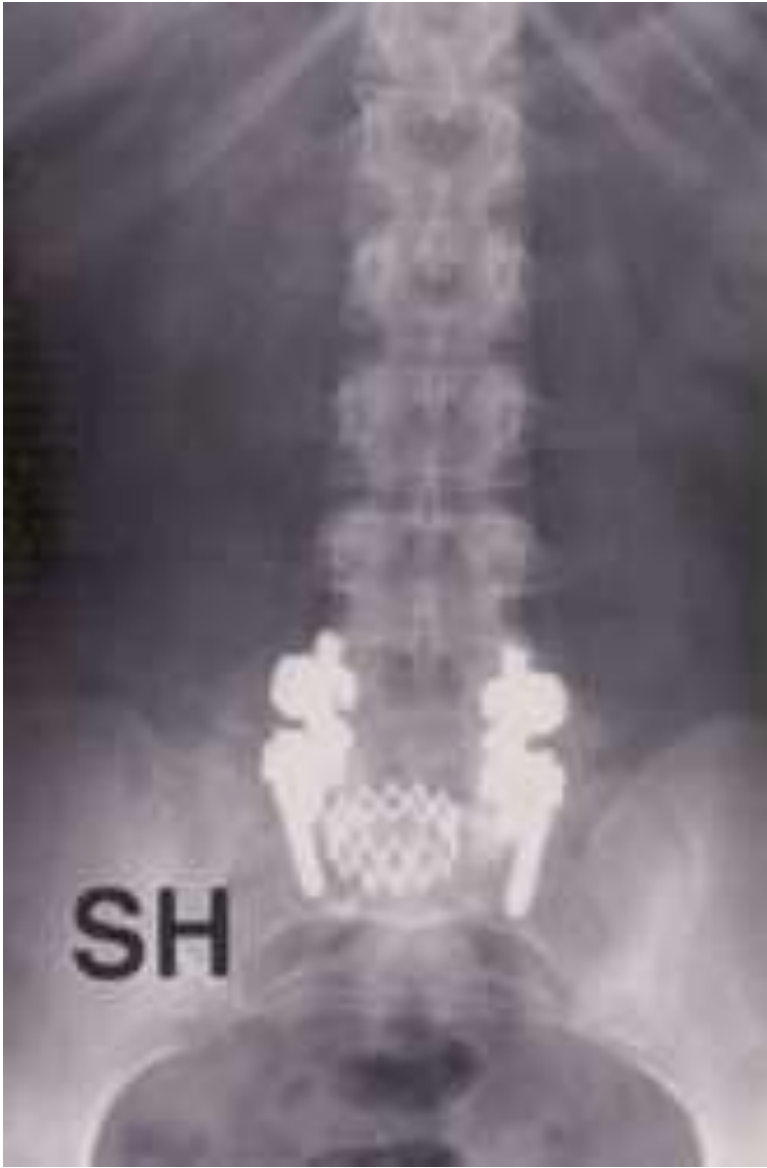- Fem, 31^a
- Dolor lumbar, radiculopatía MID
- RMN
- Cirugía: disectomía L4-L5
- Evolución: buena


















2130-08

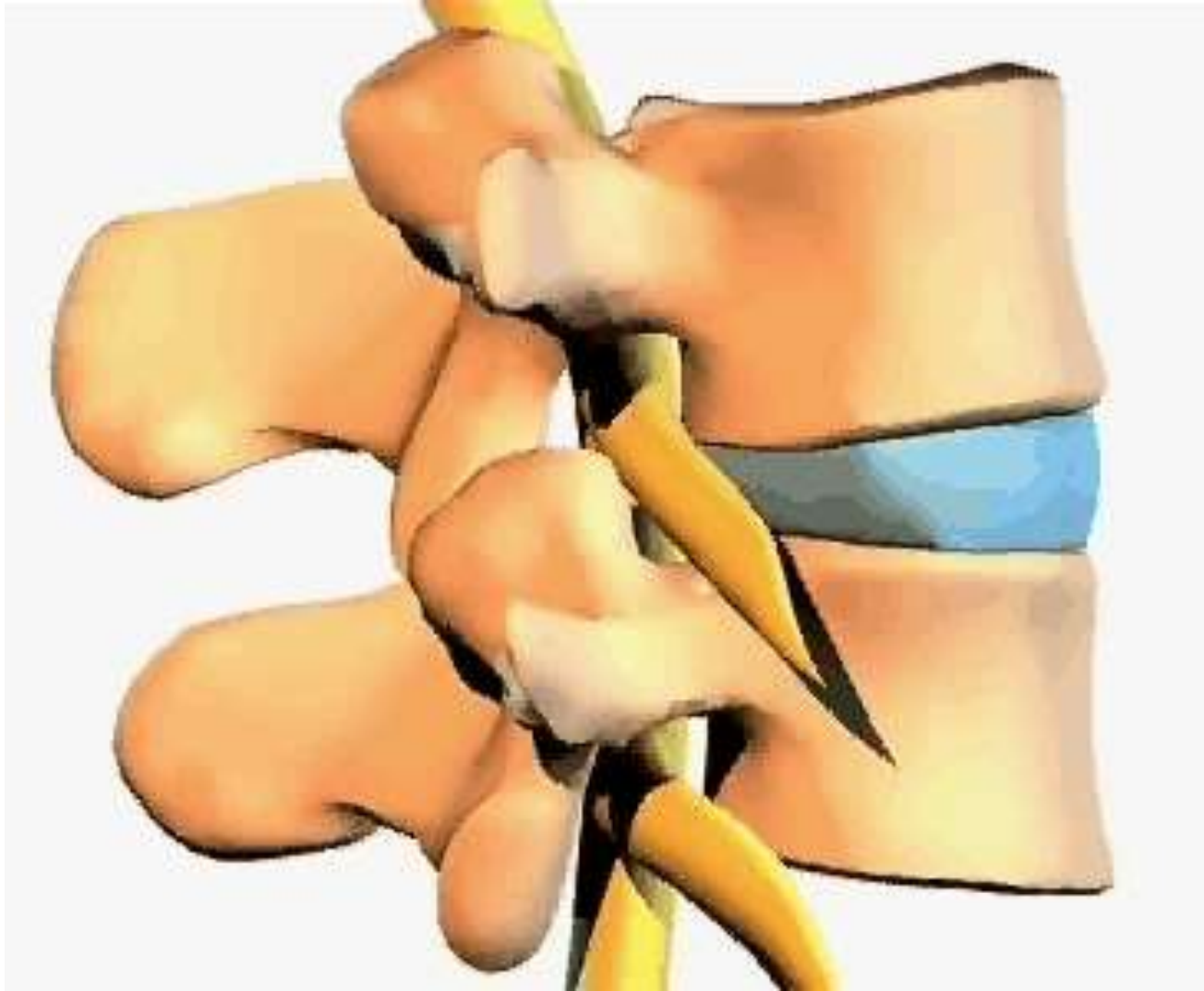
- Fem, 37^a
- Dolor lumbar, radiculopatía MII
- RMN
- Cirugía: disectomía L5-S1
- Evolución: buena

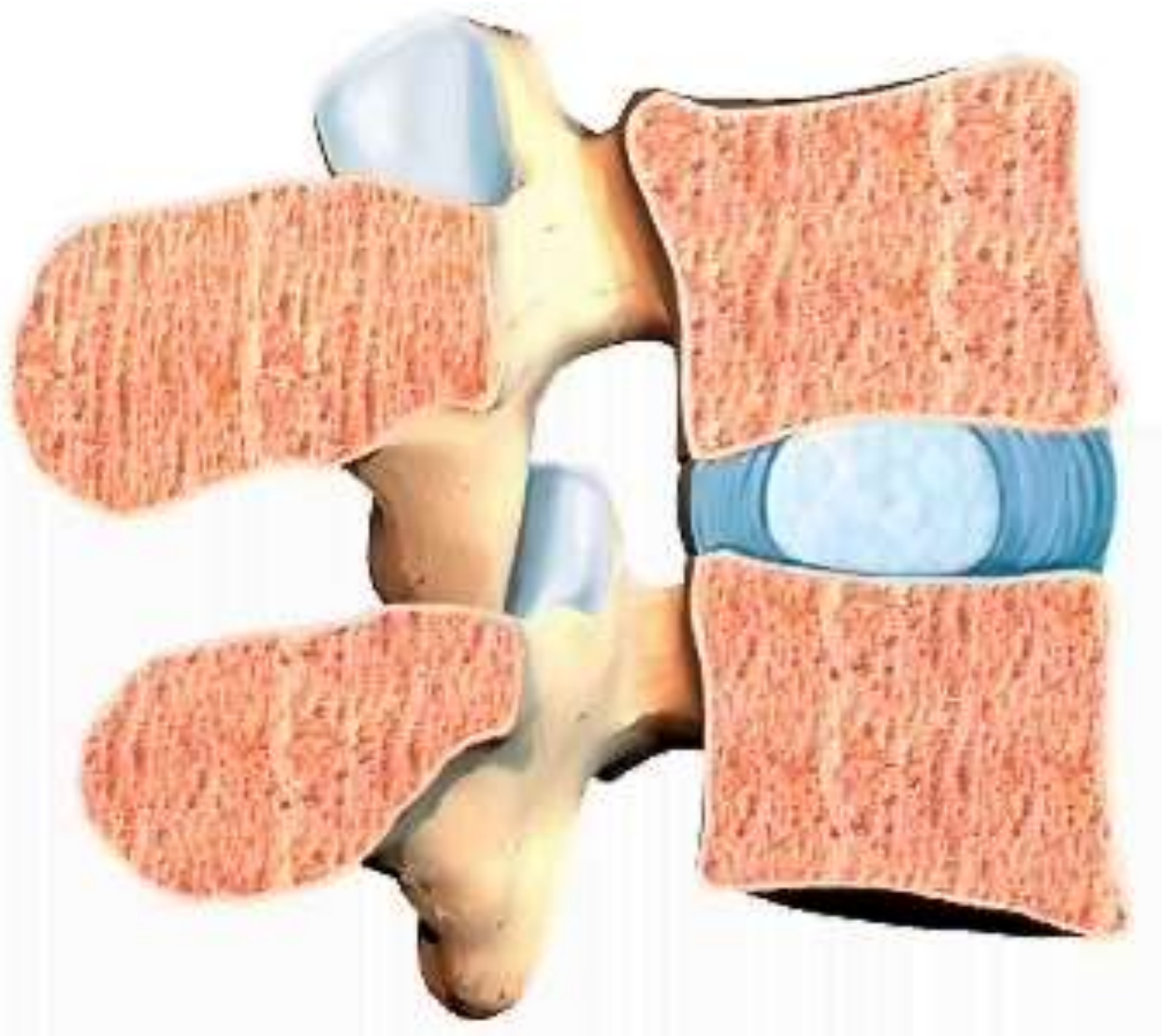


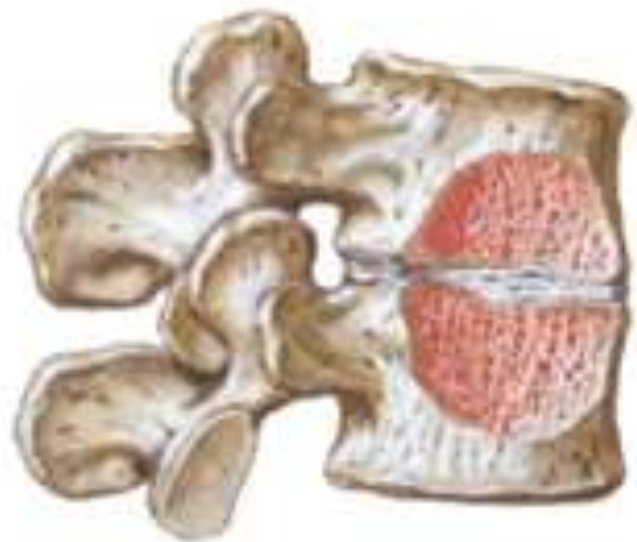
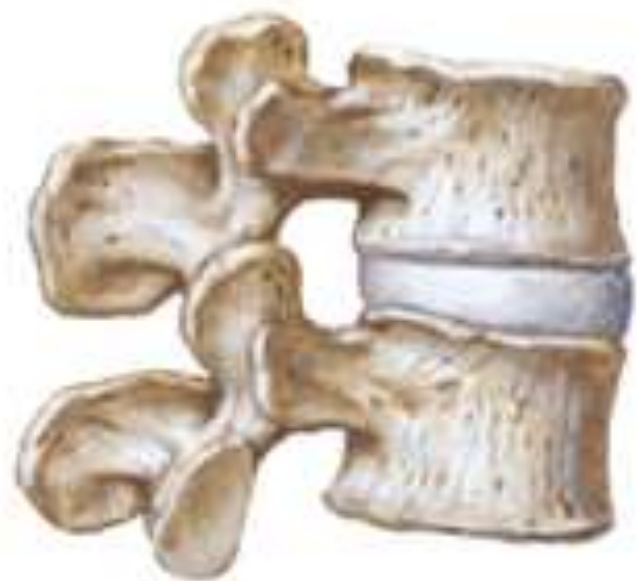

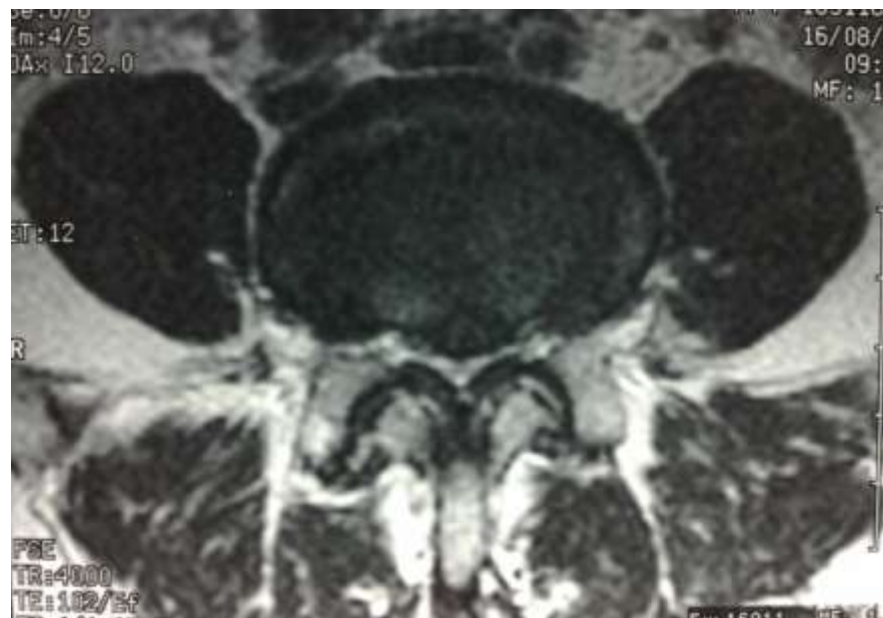
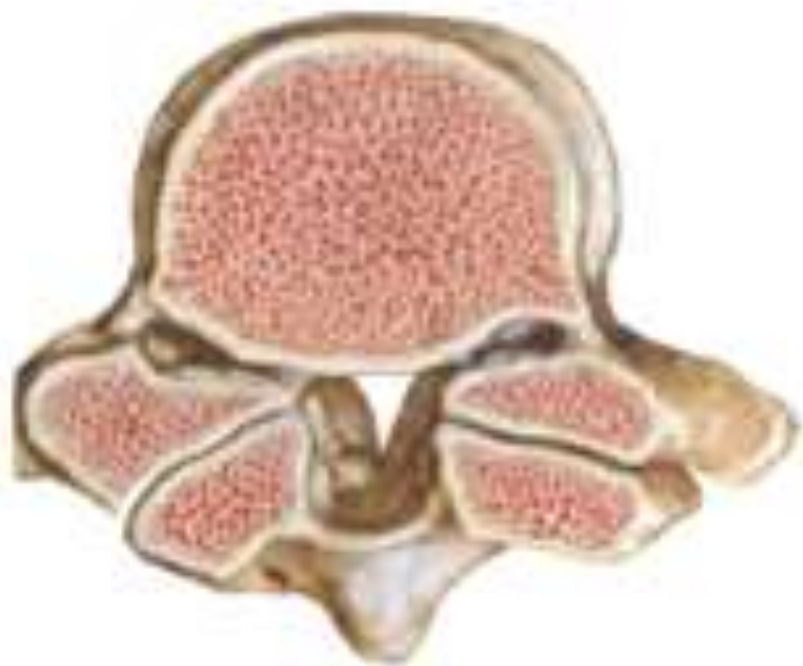Clinical Manifestations of Lumbar Disc Herniation

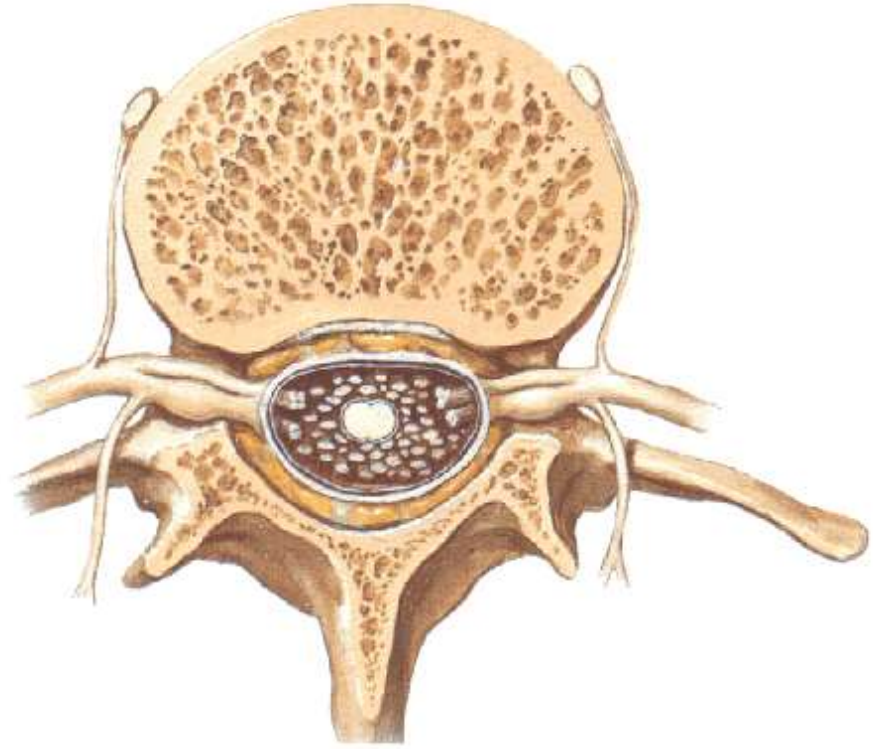
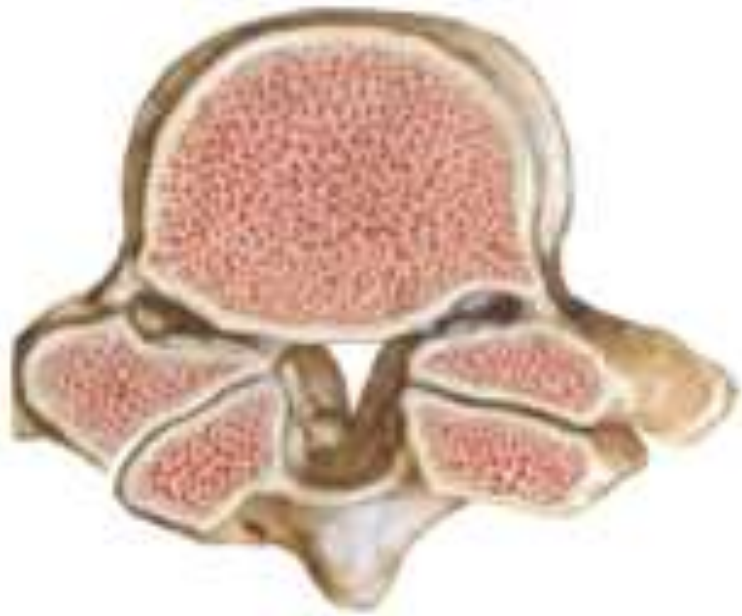Level of herniation	Pain	Numbness	Weakness	Atrophy	Reflexes
 <p>L3-4 disc; L4 nerve root</p>	 <p>Lower back, hip, posterolateral thigh, anterior leg</p>	 <p>Anteromedial thigh and knee</p>	 <p>Quadriceps</p>	 <p>Quadriceps</p>	 <p>Knee jerk diminished</p>
 <p>L4-5 disc; L5 nerve root</p>	 <p>Above sacroiliac joint, hip, lateral thigh, and leg</p>	 <p>Lateral leg, first three toes</p>	 <p>Dorsiflexion of great toe and foot; difficulty walking on heels; foot drop may occur</p>	<p>Minor or nonspecific</p>	<p>Changes uncommon in knee and ankle jerks; posterior tibial reflex diminished or absent</p>
 <p>L5-S1 disc; S1 nerve root</p>	 <p>Over sacroiliac joint, hip, posterolateral thigh, and leg to heel</p>	 <p>Back of calf, lateral heel, foot and toe</p>	<p>Plantar flexion of foot and great toe may be affected; difficulty walking on toes</p>	 <p>Gastrocnemius and soleus</p>	 <p>Ankle jerk diminished or absent</p>

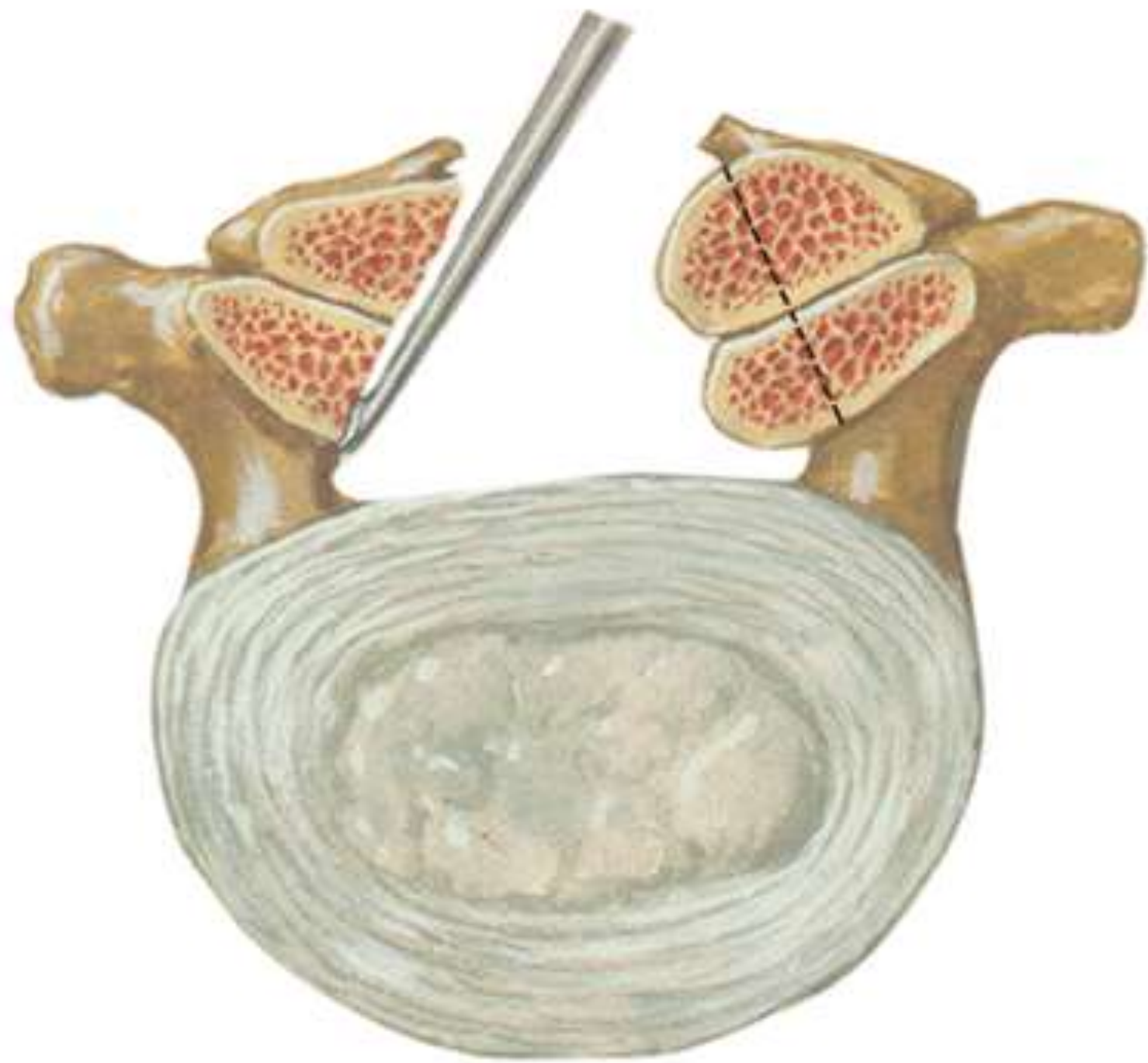






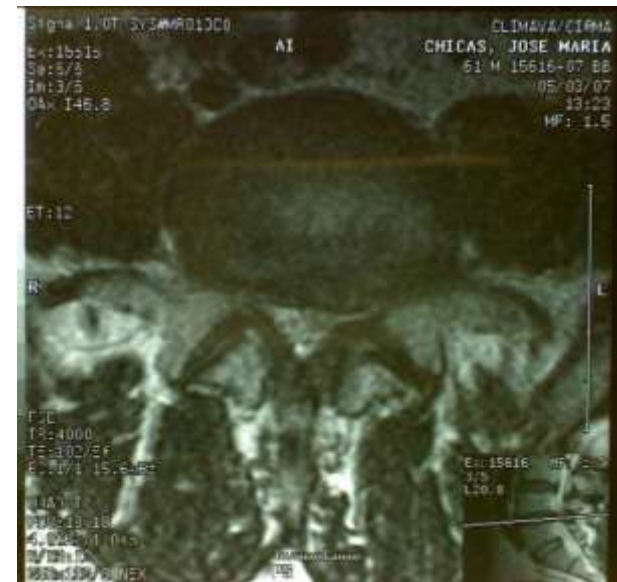
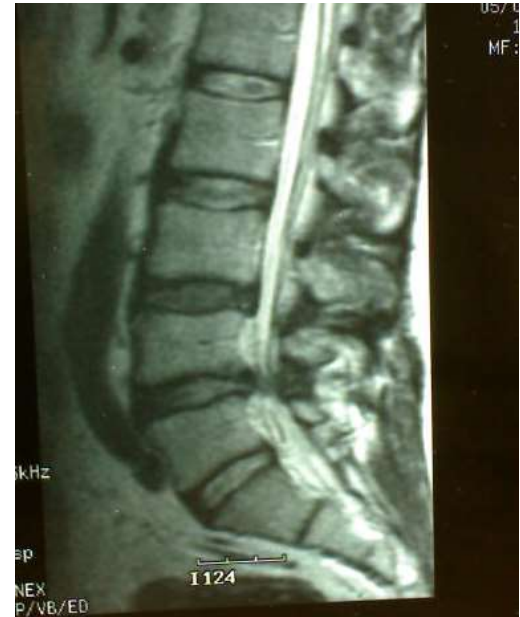



12130-04

- 61 a, M
- Dolor lumbar, claudicacion, radiculopatía
- RMN: estenosis espinal
- Cirugía: laminectomía L3 y L4
- Evolucion: adecuada



27575-06

- Masc, 50 a
- Dolor lumbar cronico
- Parestesias MII
- RMN: estenosis espinal L3-L4
- Cirugia: laminectomia
- Evolucion: alta a su casa



